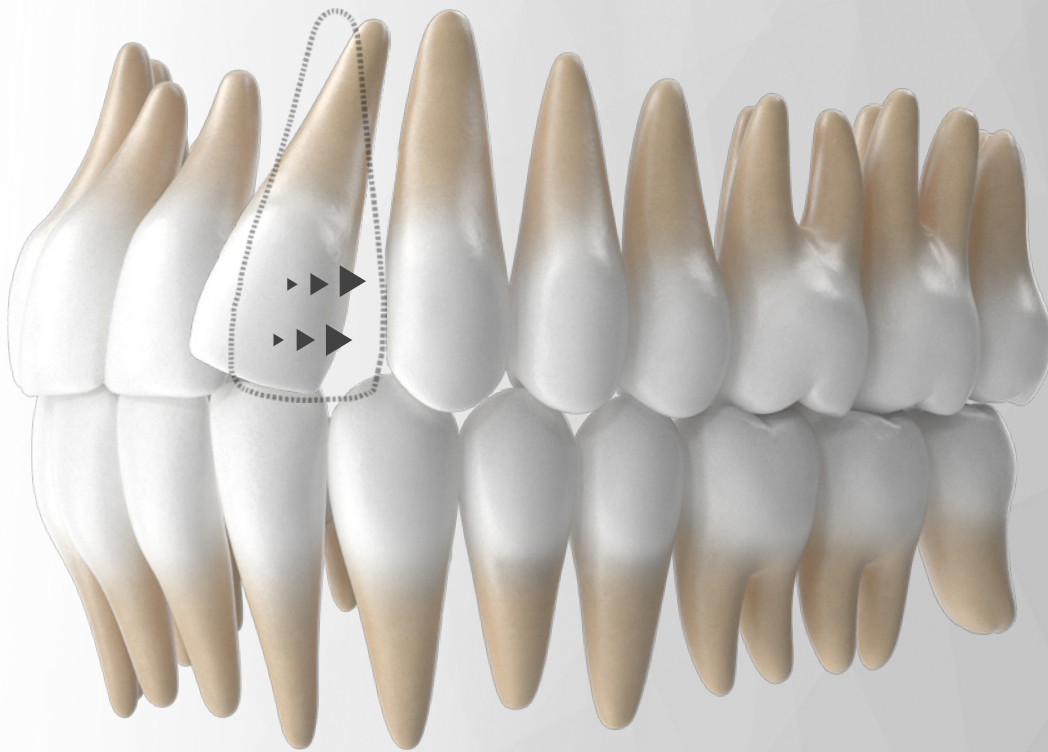


# MINOR TOOTH MOVEMENT

by DR. MARTIN B. EPSTEIN



## INTRODUCTORY COURSE

**MAY 10-11, 2024** 4 NEW COURSES

### COURSE TOPICS

1. Self-Ligation Treatment for Today and the Future
2. Advances in Treatment Approaches for Class II, Class III, Vertical Open Bites and Missing Laterals
3. Clear Removable Appliances
4. New Ideas in Early Interceptive Treatment

# CONTENTS

---

- 3 **Course Director**
- 4 **1st Course: Self-Ligation Treatment for Today and the Future**
  - Course objectives
  - Sample lecture material
- 12 **2nd Course: Advances in Treatment Approaches for Class II, Class III, Vertical Open Bites and Missing Laterals**
  - Course objectives
  - Sample lecture material
- 20 **3rd Course: Clear Removable Appliances**
  - Course objectives
  - Sample lecture material
- 27 **4th Course: New Ideas in Early Interceptive Treatment**
  - Course objectives
  - Sample lecture material
- 33 **General Information**

# COURSE DIRECTOR

---



## DR. MARTIN B. EPSTEIN

Former Clinical Associate Professor, Department of Orthodontics  
Post-Graduate Division, New York University College of Dentistry  
Diplomate of the American Board of Orthodontics  
Teacher of the Year Award – NYU College of Dentistry, Postgraduate Orthodontics  
Presented courses and seminars extensively in Europe, Asia and South America  
Written numerous articles in American and International Orthodontic publications  
American Dental Association Certificate of Recognition – for volunteer service in a foreign country  
Manuscript Review Committee: American Journal of Orthodontics and Dentofacial Orthopedics  
Private practice of Orthodontics over 30 years

## COURSE TOPICS

“How to be more successful in an era  
of non-compliant patients”

1

**Self-Ligation  
Treatment for  
Today and the  
Future**

May 10th, 2024  
09:00-13:00

2

**Advances in Treatment  
Approaches for Class II,  
Class III, Vertical Open  
Bites and Missing  
Laterals**

May 10th, 2024  
14:00-18:00

3

**Clear Removable  
Appliances**

May 11th, 2024  
09:00-13:00

4

**New Ideas in Early  
Interceptive  
Treatment**

May 11th, 2024  
14:00-18:00

## INTRODUCTORY LECTURE COURSE

# Self-Ligation Treatment for Today and the Future

### COURSE CONTENT

New ideas in treatment with self ligating brackets

New and improved bonding techniques for 100% success

New bonding agents

Current ideas on slot size for better results

The 3 archwire technique



This is part of a larger 2-year hands-on course offered by Merimna Institute. The complete course is with lectures and typodonts.



- Complete and thorough case explanations
- Each step discussed and shown in detail
- Class participation and inter-active thinking
- Diagnosis and treatment planning of actual cases from your own offices and we will follow their progress during the 2 years of the course.



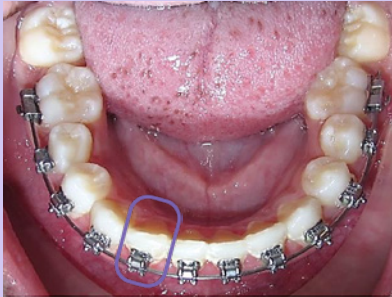

# Samples from previous courses

1st COURSE Self-Ligation Treatment for Today and the Future

## Pre-Finishing: An Artform




2nd ARCHWIRES:  
U .020 x .020 Bioforce

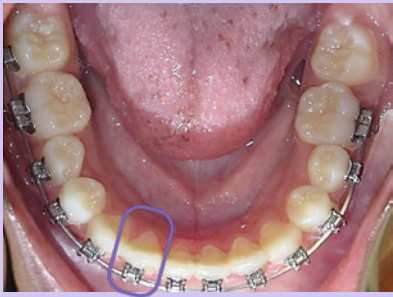


2nd ARCHWIRES:  
L .020 x .020 Bioforce

3rd ARCHWIRES:  
U .018 x .025 SS



BONDED LOWER 2nd MOLARS  
Lower left side debonded after alignment



3rd ARCHWIRES: [options]  
L .017 x .025 TMA [for 7's]

PRE FINISH

WHAT DID I MISS ?

## Results: the PROOF



FINAL



RESULTS

WHAT DID I MISS ?

REMEMBER



"ATTENTION TO DETAIL"

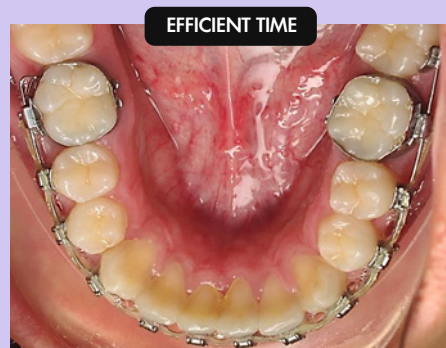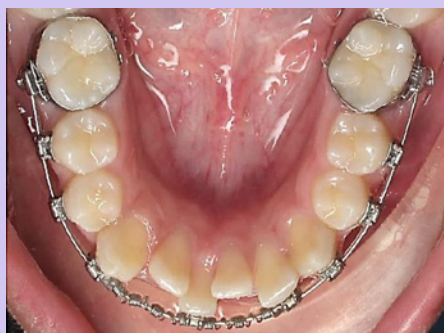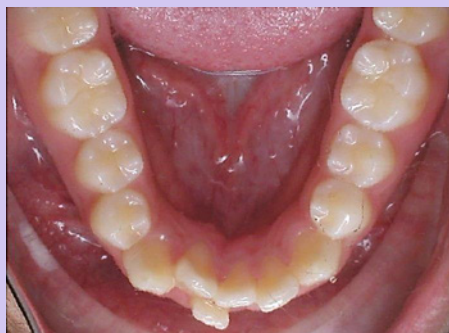IDEAL BRACKET POSIDION

 IDEAL ARCHFORM

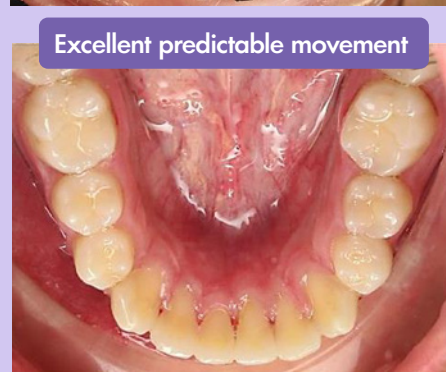# Samples from previous courses

1st COURSE Self-Ligation Treatment for Today and the Future

## Self Ligation: More "Efficient" Time



**EFFICIENT TIME**

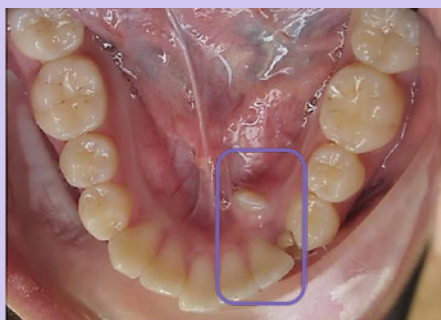


**Excellent predictable movement**

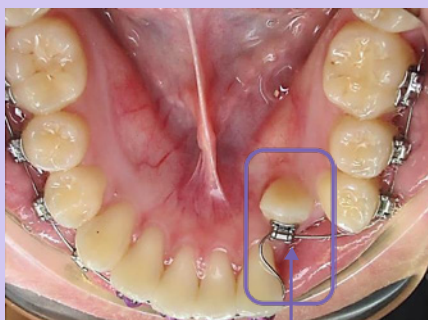
## Ease of treatment with severe or "supper-rotations"

**INDIVIDUAL TEETH**

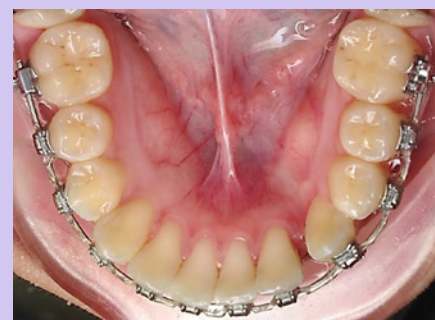
**CANINE LINGUALLY DISPLACED  
WITH NO SPACE**



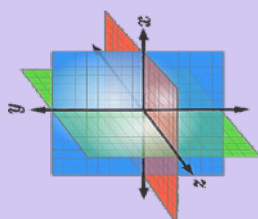
**LIGHT FORCE DELIVERY**  
Initial bonding of canine  
ACTIVE COIL OPENED SPACE




**IMPROVED CANINE POSITION**  
2 visits [16 weeks]



**3 PLANES OF "FREEDOM"**



**Active Clip Mechanism**



**Simple Mechanism**



# Samples from previous courses

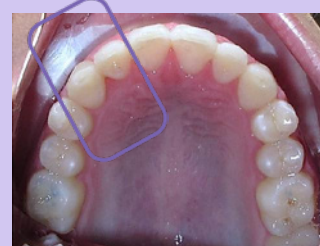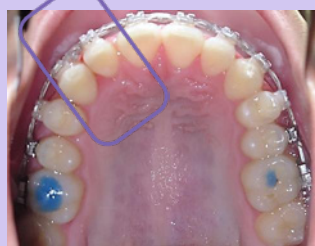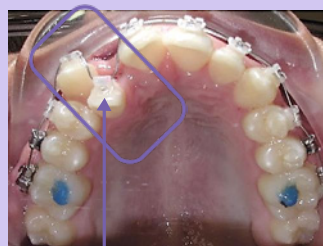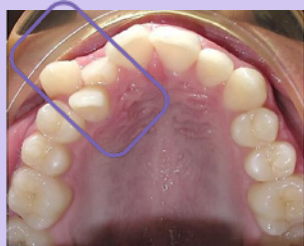1st COURSE Self-Ligation Treatment for Today and the Future

## Ease of treatment with severe or "supper-rotations"

INDIVIDUAL TEETH

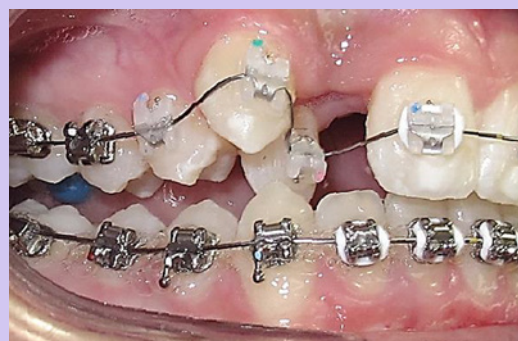
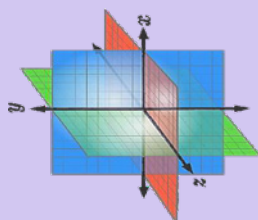
**LIGHT FORCE DELIVERY**  
Lateral incisor directly behind canine  
[after removal of supernumerary]

Can engage almost any tooth.....In any clinical situation  
with simple treatment mechanics



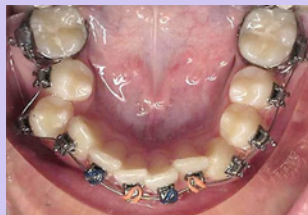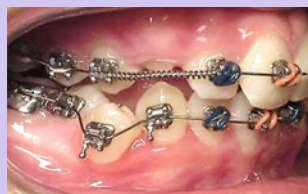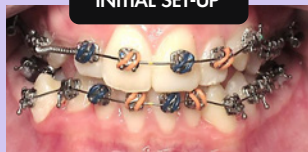Active Clip Mechanism

3 PLANES OF "FREEDOM"

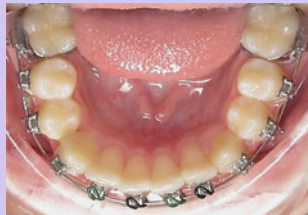
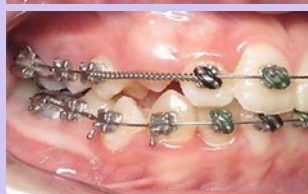
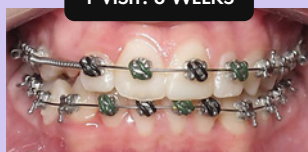## Self Ligation: smaller wire sizes with lighter forces

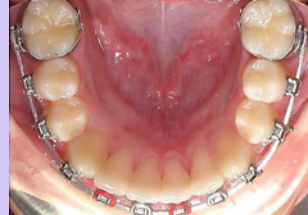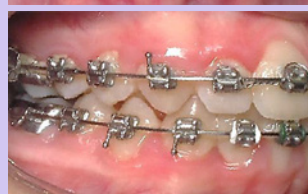
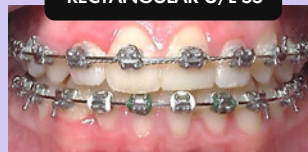INITIAL SET-UP



1 VISIT: 8 WEEKS



RECTANGULAR U/L SS

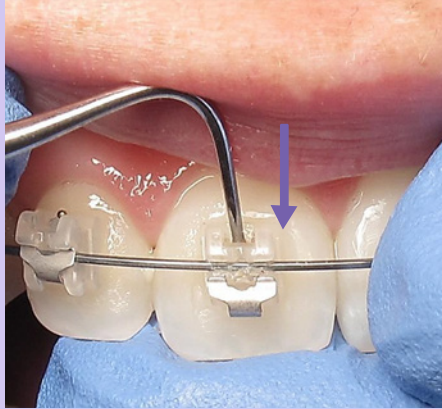
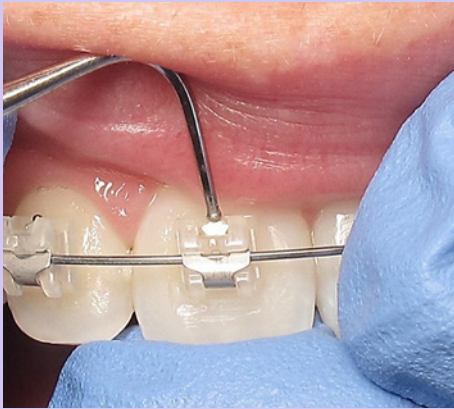


L A T E T X P R O G R E S S

# Samples from previous courses

1st COURSE Self-Ligation Treatment for Today and the Future

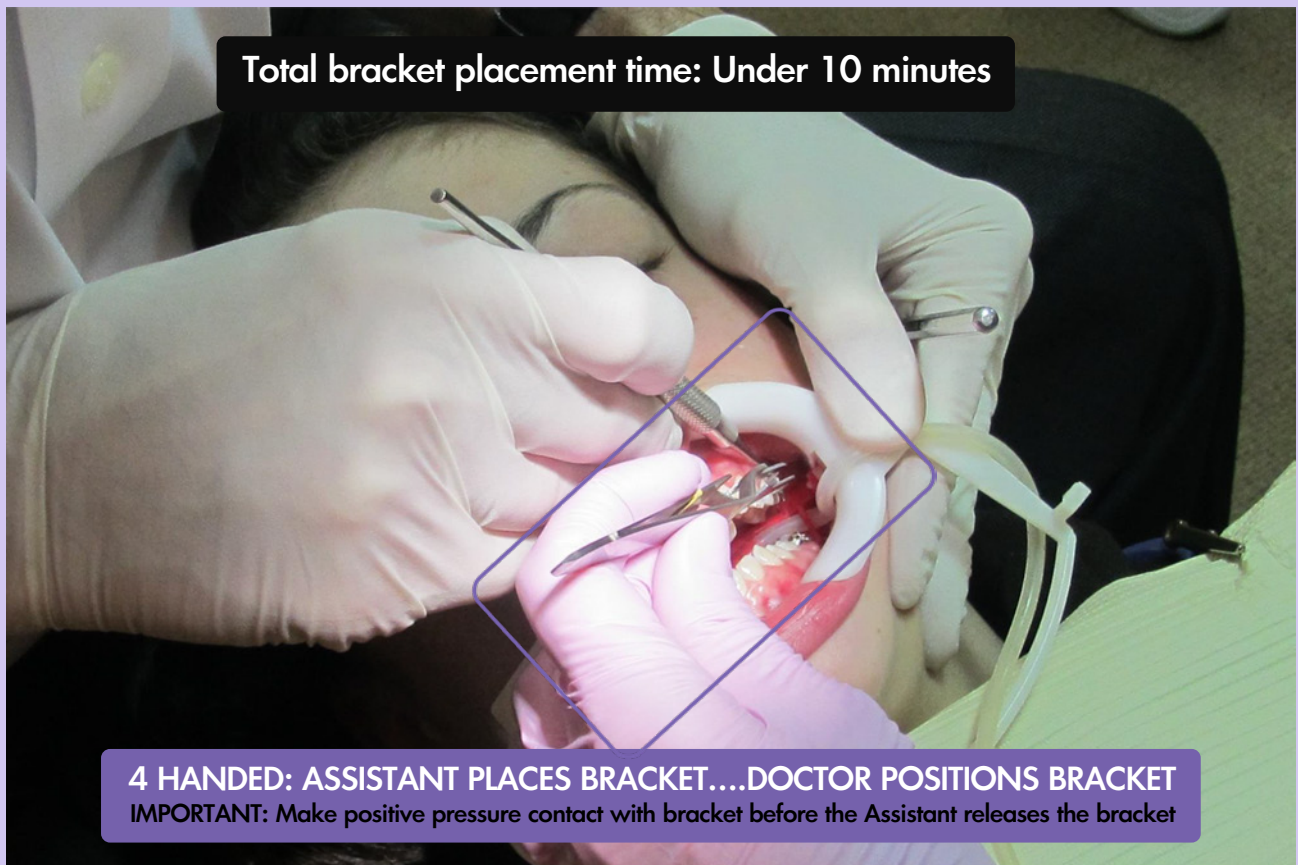
## Self Ligation: increased staff efficiency **ADVANTAGE**



### INSTRUMENTATION: EASY-TO-OPEN

Angulate ball from the gingival  
Support the tooth from incisal and press  
Clip slides OPEN

## Full Technique with Nola Retractor and Bracketing



Total bracket placement time: Under 10 minutes

**4 HANDED: ASSISTANT PLACES BRACKET....DOCTOR POSITIONS BRACKET**


**IMPORTANT: Make positive pressure contact with bracket before the Assistant releases the bracket**




# Samples from previous courses

1st COURSE Self-Ligation Treatment for Today and the Future

## BONDING UPDATES



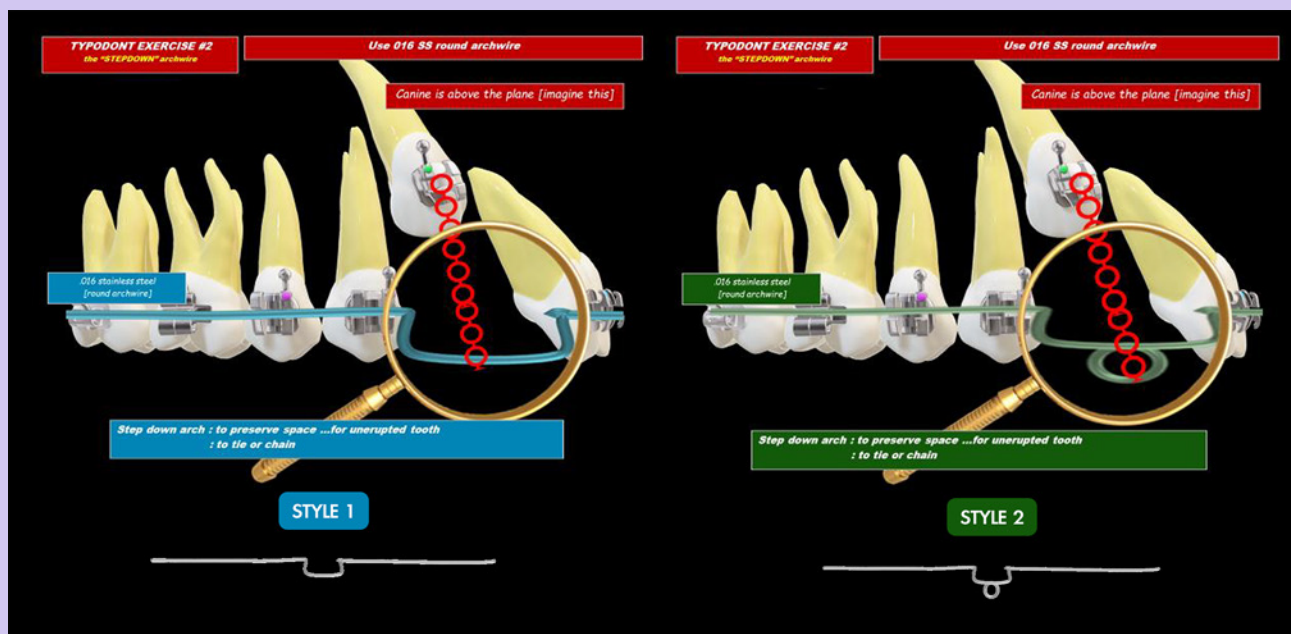
Preload the light-cured bonding resin to brackets  
Up to 3-4 days in advance [NOT 1 WEEK]



Setup multiple sets of brackets  
Up to 3-4 days in advance

## TYPODONT EXERCISES

### FOR MALPOSED TEETH [CANINES]

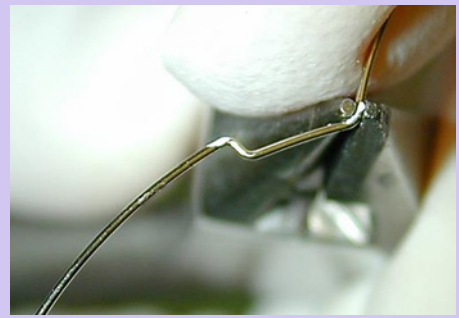
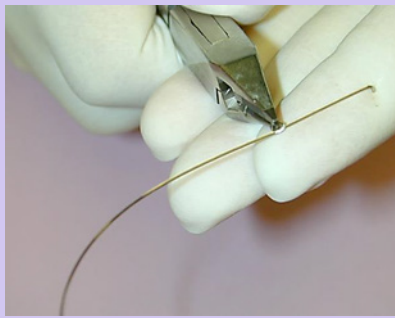
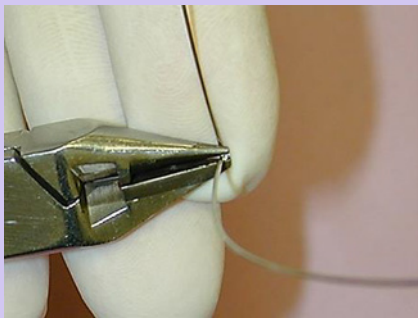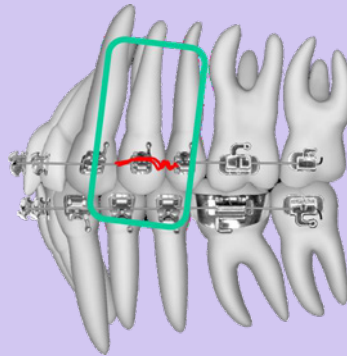


# Samples from previous courses

1st COURSE Self-Ligation Treatment for Today and the Future

## TYPODONT EXERCISES

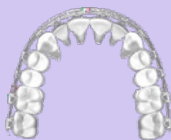WIRE BENDING  
MODIFYING ARCHWIRES  
ACTIVE & PASSIVE COIL



## TYPODONT EXERCISE TOPICS

### MODEL SET #2

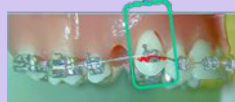1. Archwire placement



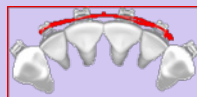2. Archwire cinching



3. Steel ligature ties [single ties]



4. Steel figure 8 ties [2-2]



5. Power chain



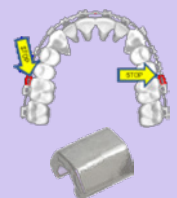6. Active coil



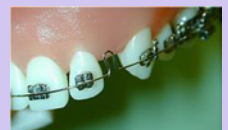7. Passive coil



8. Crimpable stops

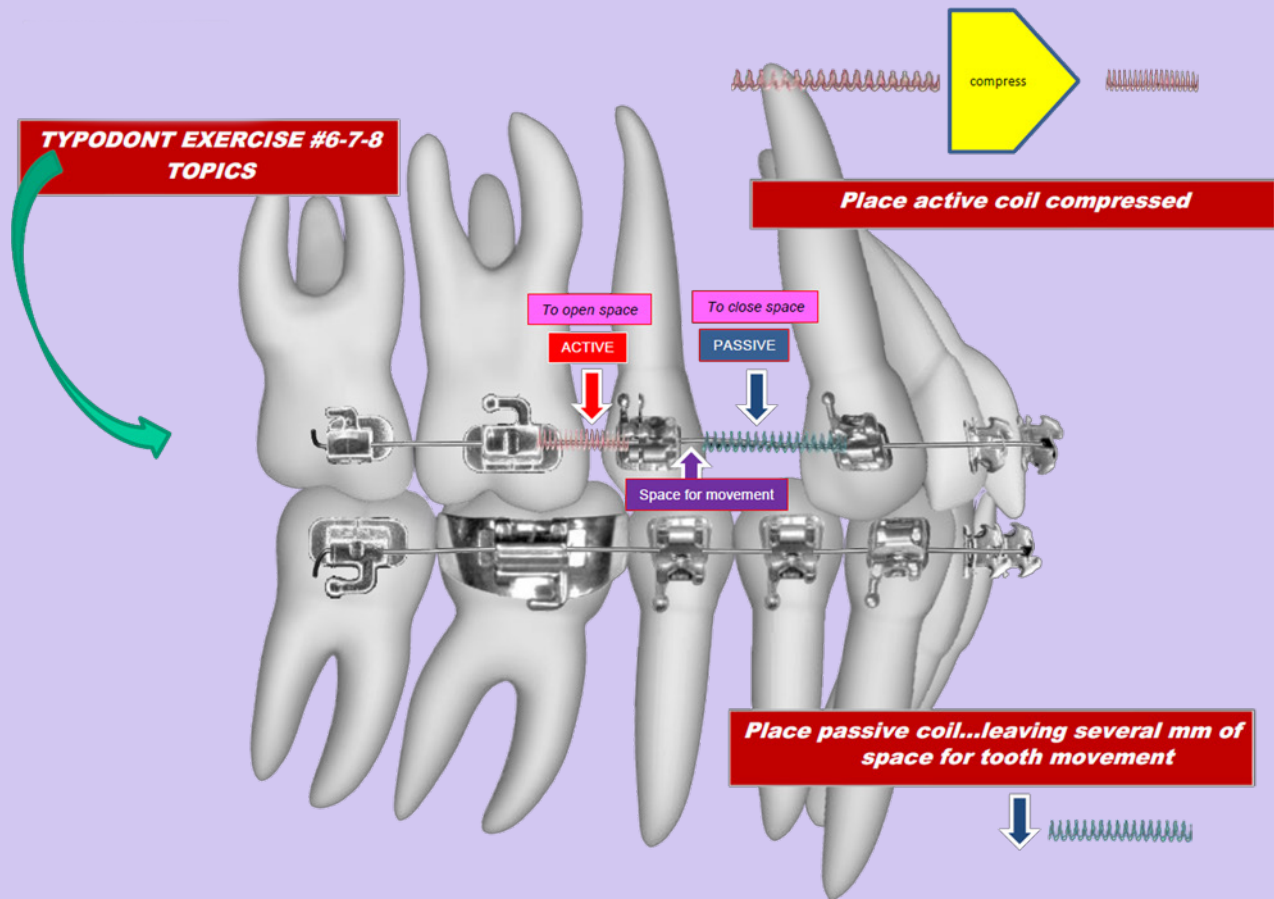


9. Archwire bends  
[.018 SS] circles & loops



# Samples from previous courses

1st COURSE Self-Ligation Treatment for Today and the Future



## LECTURE COURSE

# Advances in Treatment Approaches for Class II, Class III, Vertical Open Bites and Missing Laterals

## COURSE CONTENT

### CLASS II

Alternatives to Class II elastics  
The most successful uses of Maxillary distalizing appliances  
Is the Herbst Appliance still the choice for mandibular deficiencies  
Easier and more compliant appliances for mandibular deficiencies

### CLASS III

New treatment strategies that really work  
Early intervention strategies  
Surgery first approaches

### VERTICAL OPEN BITES

How to solve these most difficult malocclusions

### TREATMENT OF MISSING LATERAL INCISORS

Treatment planning: open or close the space for missing laterals  
Proper strategy to create ideal implant spacing  
How to fabricate esthetic pontics during treatment



This is part of a larger 2-year hands-on course offered by Merimna Institute. This is a course in advanced treatment knowledge.

- Advanced treatment approaches for Class II including distalization appliances.
- Advanced treatment approaches for Class III that really work and give great results.
- Class III early intervention methods besides and different from Face Masks.
- Vertical open bite treatment strategies
- How to treat congenitally missing upper lateral incisors
- When to close spaces for laterals and when to open spaces and how to make pontics that work easily with fixed appliances.



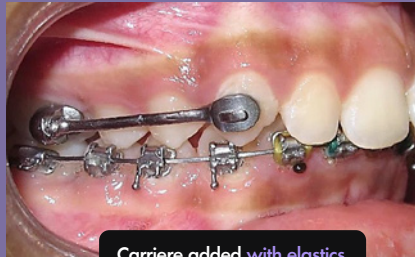
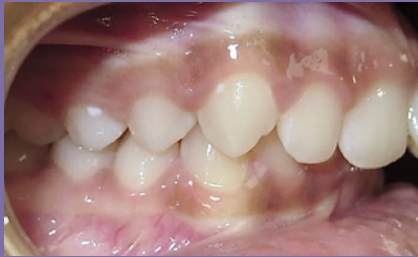# Samples from previous courses

2nd COURSE Advances in Treatment Approaches for Class II, Class III, Vertical Open Bites and Missing Laterals

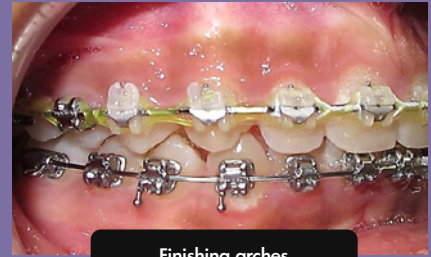
## Class II correction with Carriere Appliance

Excessive overjet corrected

Deep bite corrected

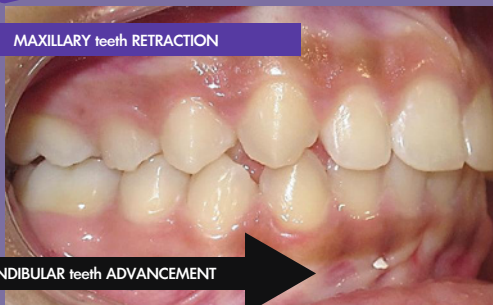

Carriere added with elastics



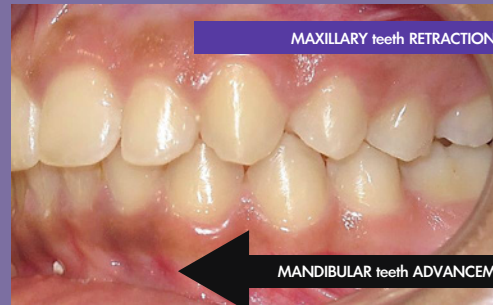
Finishing arches

### RESULTS



MAXILLARY teeth RETRACTION

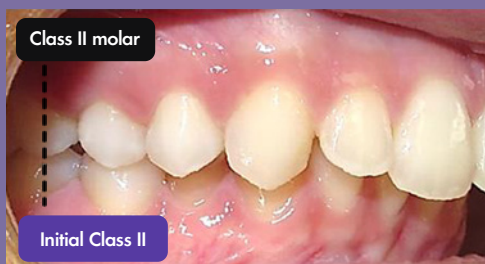MANDIBULAR teeth ADVANCEMENT



MAXILLARY teeth RETRACTION

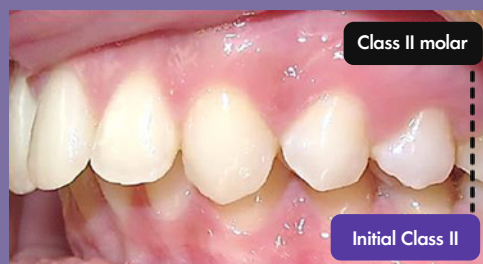MANDIBULAR teeth ADVANCEMENT

## Class II correction with maxillary molar distalization in a teenager WITH ALIGNER TX



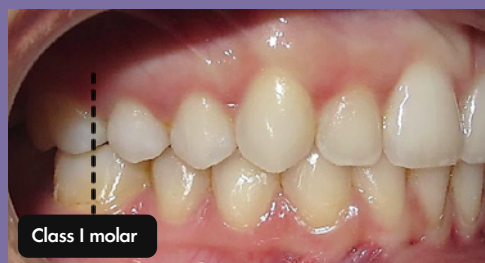Class II molar

Initial Class II

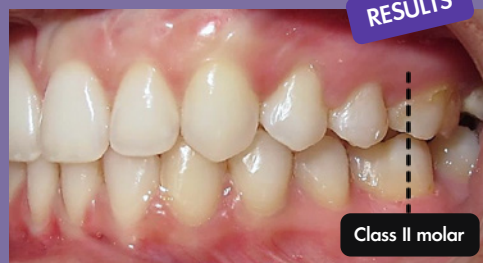

Class II molar

Initial Class II



Class I molar



### RESULTS

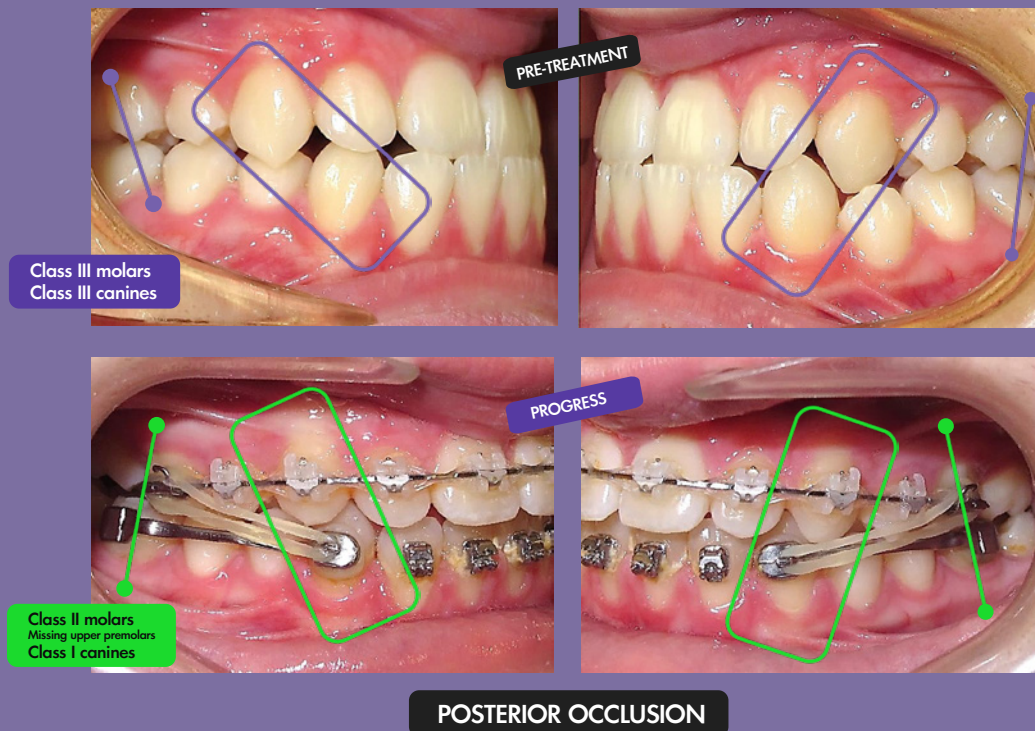
Class II molar

FINAL CLASS I OCCLUSION

# Samples from previous courses

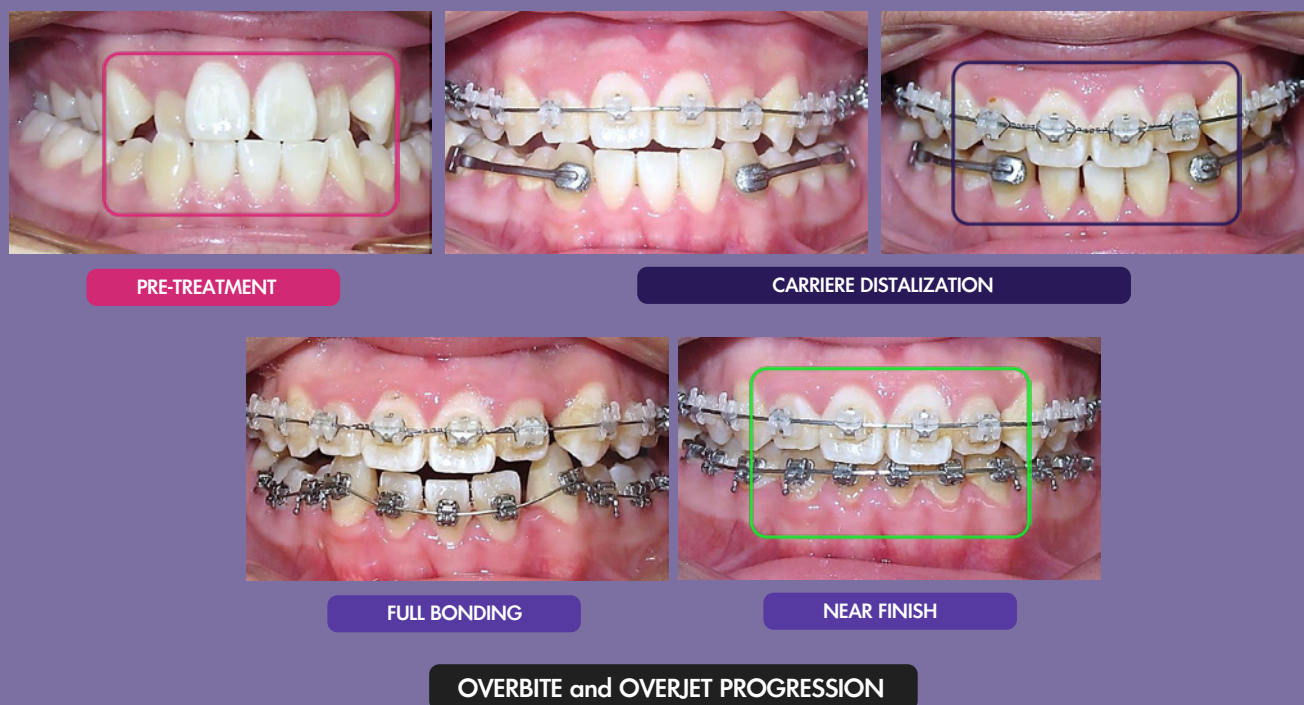
2nd COURSE Advances in Treatment Approaches for Class II, Class III, Vertical Open Bites and Missing Laterals

## CASE #BP: "CLASS III " ...treatment with Carriere



## CASE #AI: "CLASS III " ...treatment

POSITIVE OVERJET ESTABLISHED  
POSITIVE VERTICAL OVERBITE ESTABLISHED

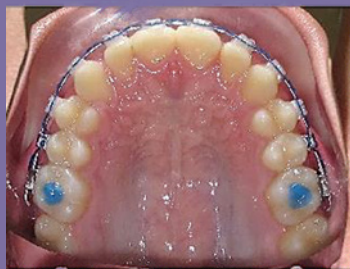
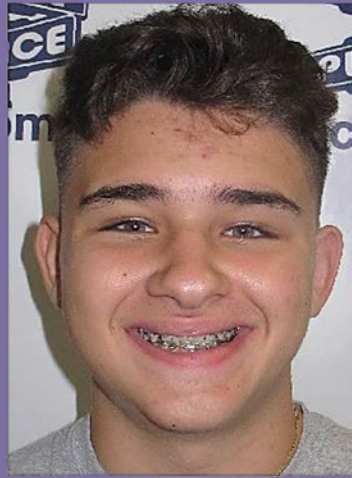


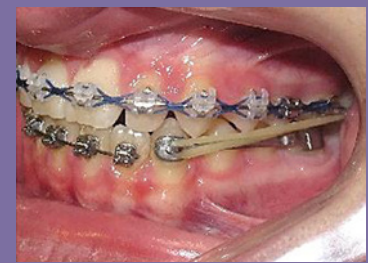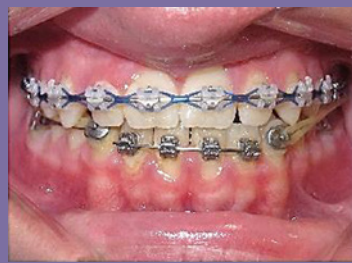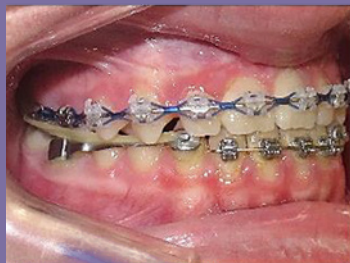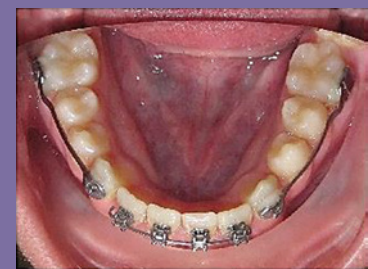# Samples from previous courses

2nd COURSE Advances in Treatment Approaches for Class II, Class III, Vertical Open Bites and Missing Laterals

## CASE #DK: "CLASS III " ...treatment



AGE 13.9  
4 MONTHS PROGRESS  
ESTABLISHED POSITIVE OB/OJ  
CLASS III CARRIERE APPLIANCE  
with  
CLASS III ELASTICS [6 oz ¼ FORCE 1]

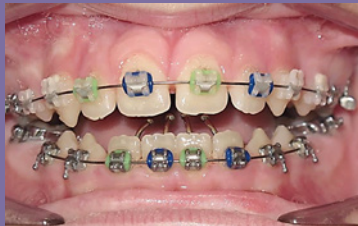

# Samples from previous courses

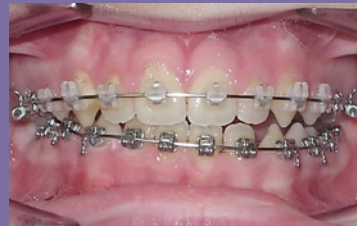2nd COURSE Advances in Treatment Approaches for Class II, Class III, Vertical Open Bites and Missing Laterals

## STRATEGIES:

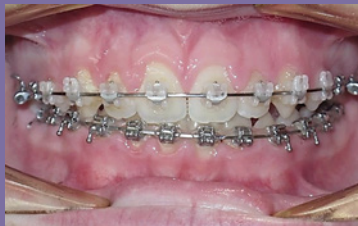### 4. Use auxiliary appliances [tongue loops, tongue tamers, TPA, RPE]



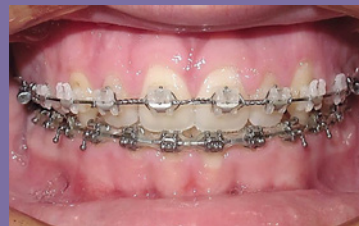Initial bonding with lower tongue loops



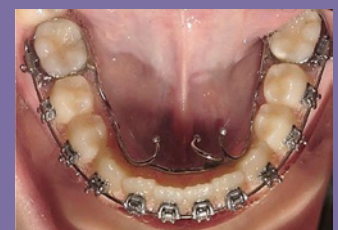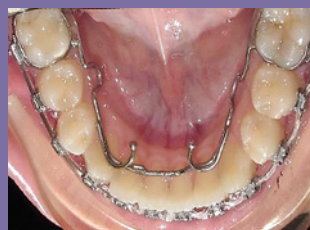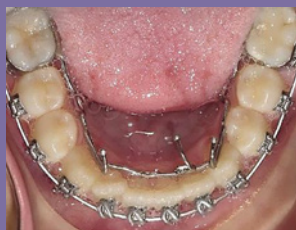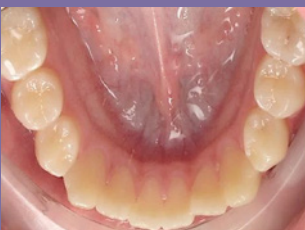
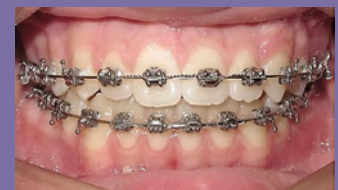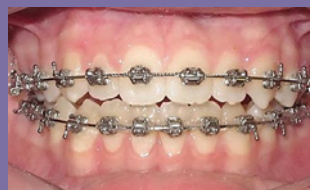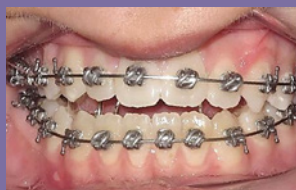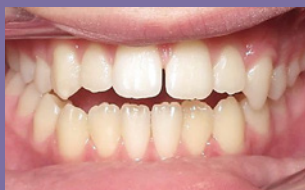12 months-tongue loops still present



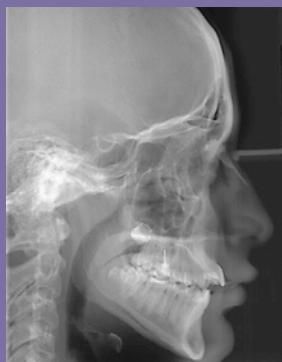17 months lower tongue loops ready to remove



22 months open bite fully closed



Auxiliary Appliance: Lower lingual bar with tongue loops

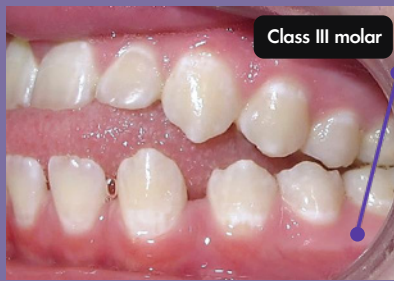
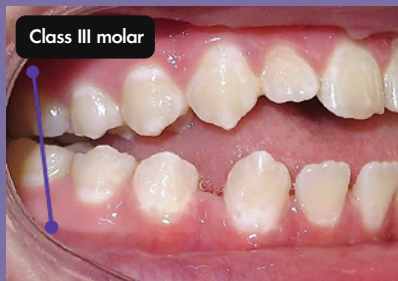


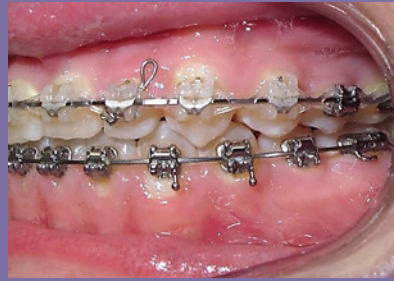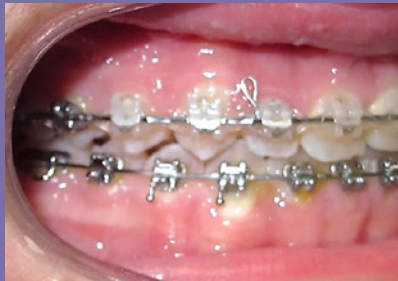# Samples from previous courses

2nd COURSE Advances in Treatment Approaches for Class II, Class III, Vertical Open Bites and Missing Laterals

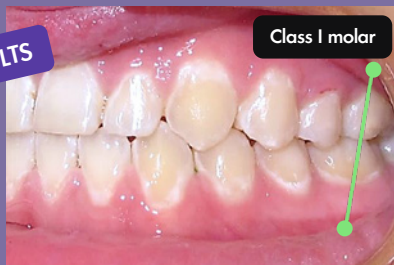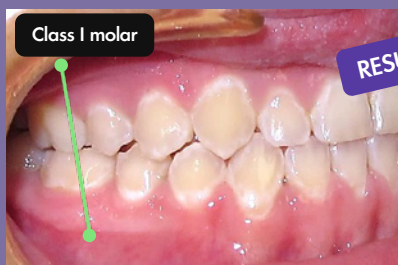## Class III : with SEVERE anterior openbite



PRE-TREATMENT



MID-TREATMENT

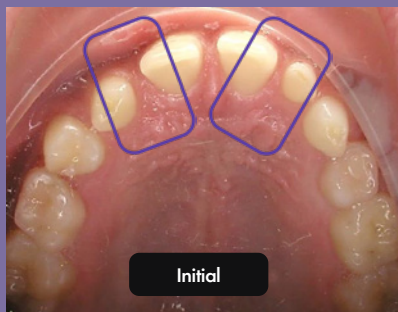

RESULTS

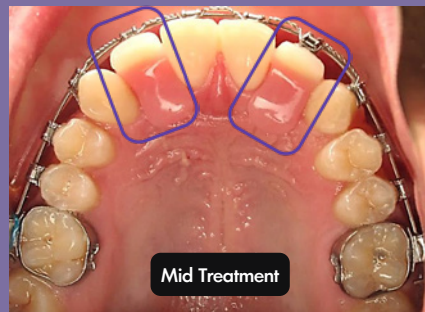
POST-TREATMENT

## Treatment Progress: Agenesis of both upper lateral incisors

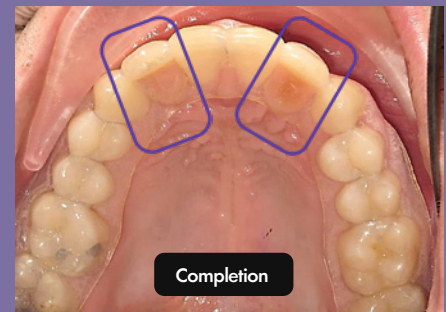
Upper arch with no crowding and spacing



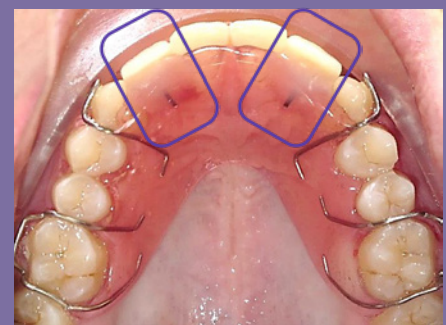
Agenesis Both Upper Laterals



Spaces Opened & Pontics Placed



Retainers Placed with Pontics

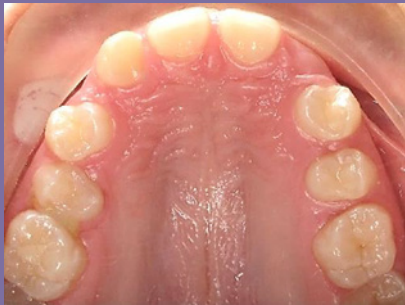

# Samples from previous courses

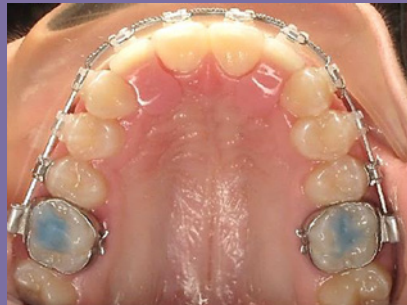2nd COURSE Advances in Treatment Approaches for Class II, Class III, Vertical Open Bites and Missing Laterals

## Class II [Type C] Mandibular Retrognathia, Mandibular Procumbency

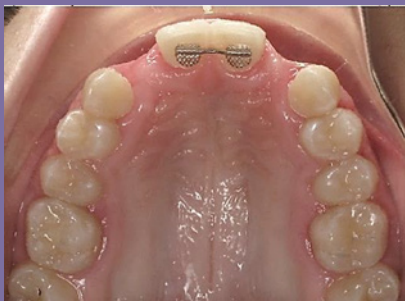Upper arch with no crowding and spacing



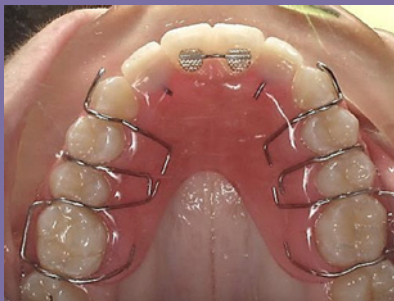
PRIOR TO TREATMENT



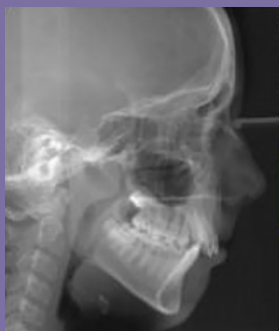PONTICS PLACED



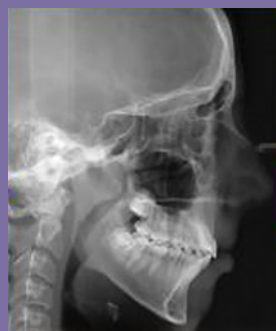RETAINERS PLACED



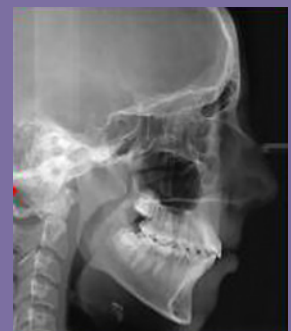## Female Adolescent Time Line



GROWTH



GROWTH  
COMPLETED



**PRE-TREATMENT**  
Usually age 11-13

Treatment

**APLASIA TREATMENT**  
Usually completed age 13-14

2 Years ?

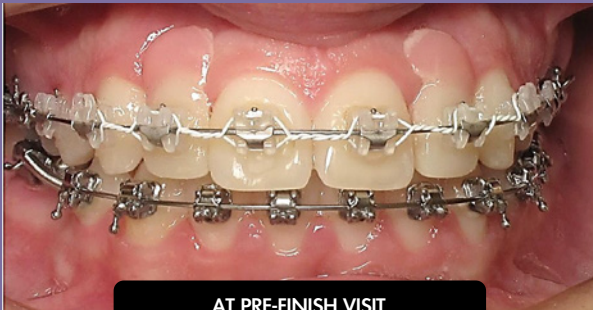**IMPLANT PLACEMENT**  
Growth completed age 16-18



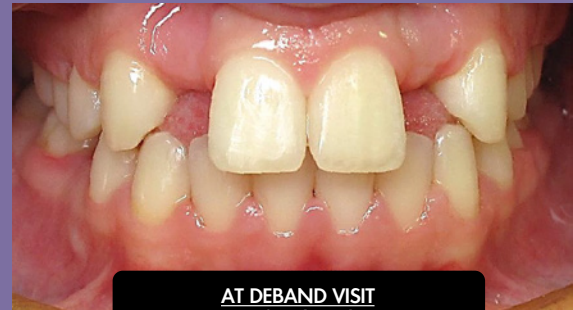# Samples from previous courses

2nd COURSE Advances in Treatment Approaches for Class II, Class III, Vertical Open Bites and Missing Laterals

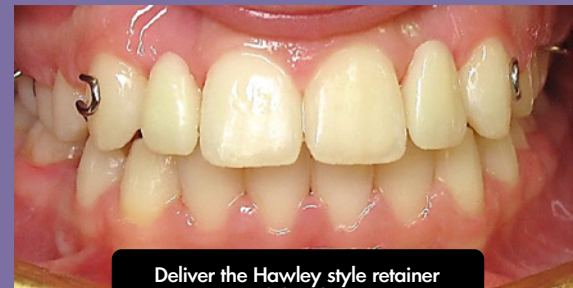## CLINICAL KEY POINTS for ideal interim retention



**AT PRE-FINISH VISIT**  
Remove pontics  
Take impression for retainer [or scan]  
Put pontics back into arch  
To have ready for deband



**AT DEBAND VISIT**  
Remove fixed appliances  
Send the 2 treatment pontics to lab  
Will make a clear retainer using  
same pontics

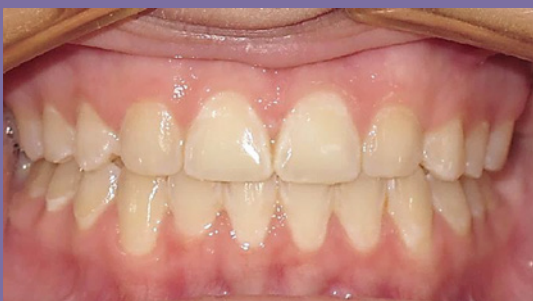
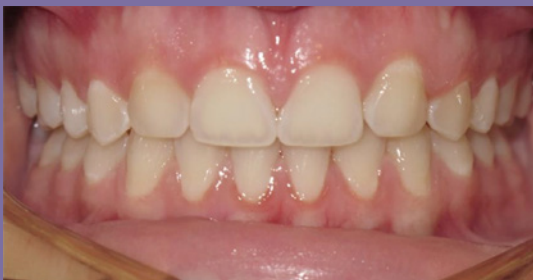
Deliver the Hawley style retainer  
No labial bow  
Use 3-3 elastic

## Treatment FINISH: Agensis of both mx lateral incisors

Treatment Options: Canine substitution

Which bracket to use ?



SEVERAL EXCELLENT CHOICES:

CORRECT CHOICES:

- Use same side canine flipped upside down [remove hook]

Good crown adaptation, increased root torque [+7]

- Use opposite side lower 2nd premolar flipped  
upside down [remove hook]

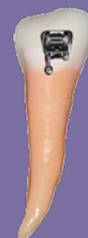Good crown adaptation, increased root torque [+17]

YES  
Upper canine



BRACKET UPSIDEDOWN

YES  
Upper canine



YES  
Lower 2nd Bi

OPPOSITE SIDE NO HOOK



YES  
Lower 2nd Bi

## LECTURE COURSE

# Clear Removable Aligners for \*\*\* Total Treatment

### COURSE CONTENT

Case selection and strategy for adolescent treatment

Class II and Class III treatment

Treatment of open and deep bites

Interdisciplinary cases with pontics

Combination treatment using fixed appliances and clear removable appliances together



This is part of a larger 2-year hands-on course offered by Merimna Institute. This is a course in advanced treatment knowledge.

- Case selection and strategy for Adolescent treatment..Teenager Treatment
- Class II and Class III correction with clear Aligners
- Treatment of Open and Deep bites with Clear Aligners
- Interdisciplinary Treatment with implants and pontics
- Combined treatment with fixed braces and clear removable aligner
- Options for making your own aligners and pontics in your office

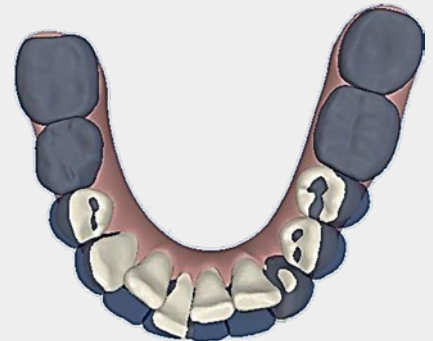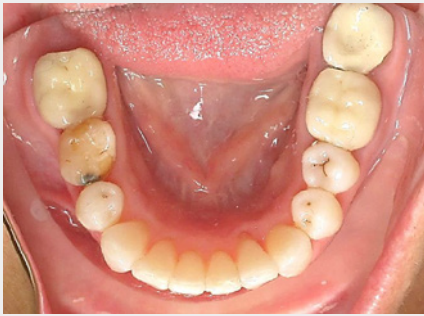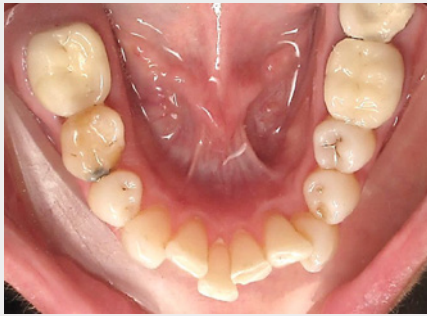
**\*\*\*THESE ARE DIFFERENT TOPICS AND CASES NOT SHOWN IN  
THE MAY 2024 COURSE AT MERIMNA INSTITUTE.**



# Samples from previous courses

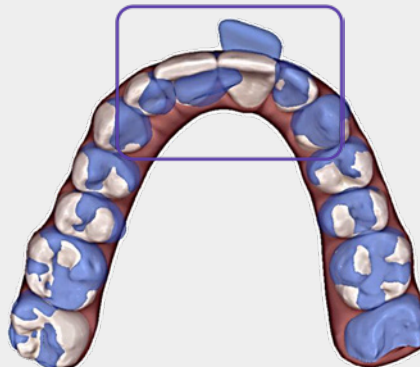
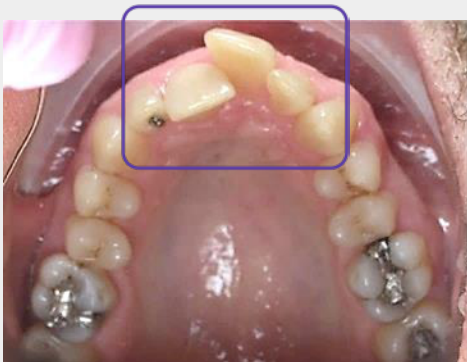3rd COURSE Clear Removable Aligners for Total Treatment

## SEVERE CROWDING NON-EXTRACTION: RESULTS and Superimposition

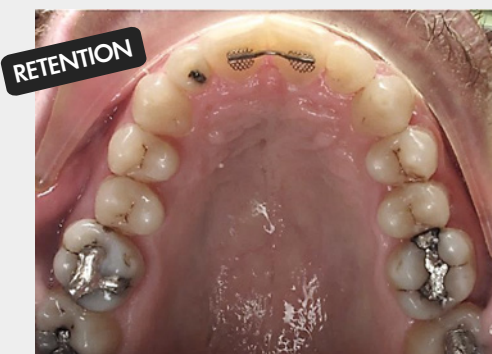
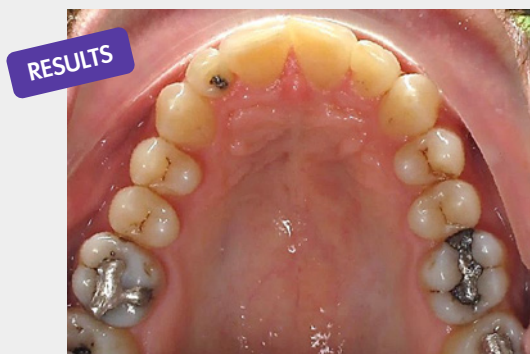
SUPERIMPOSITION OF MOVEMENT  
Widen buccal corridors  
Advance lower incisors  
BLUE IS FINAL

## SEVERE CROWDING NON-EXTRACTION: Use of IPR



SUPERIMPOSITION  
White is final



# Samples from previous courses

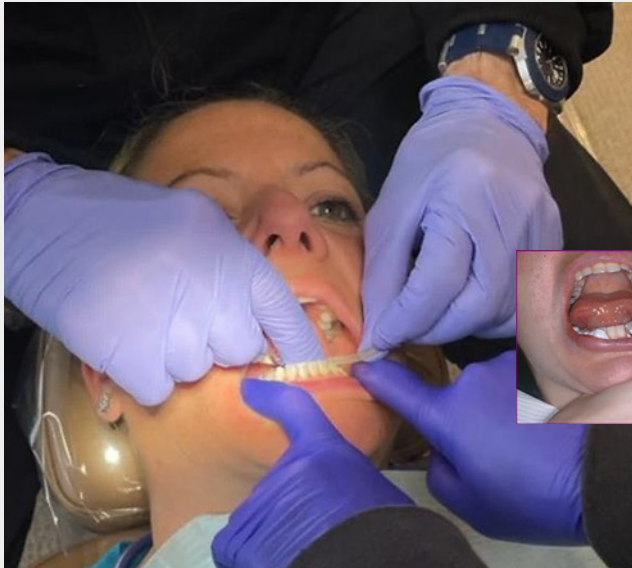
3rd COURSE Clear Removable Aligners for Total Treatment

CAT: Clear Aligner Treatment

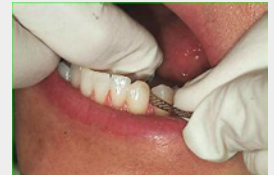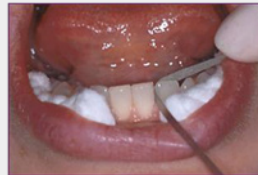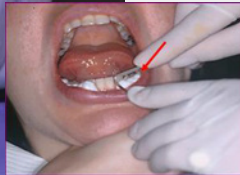BONDING ATTACHMENTS



IPR



DOCTOR TIME



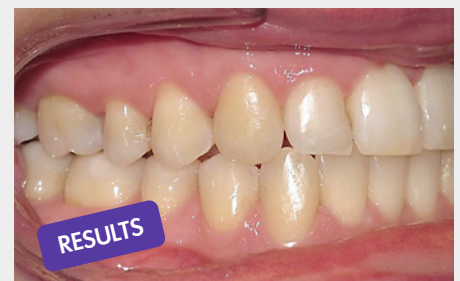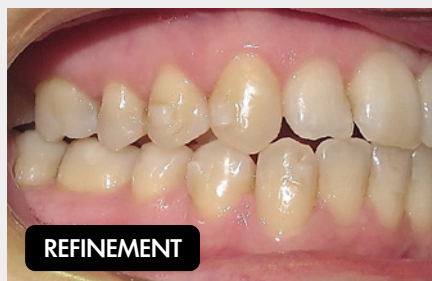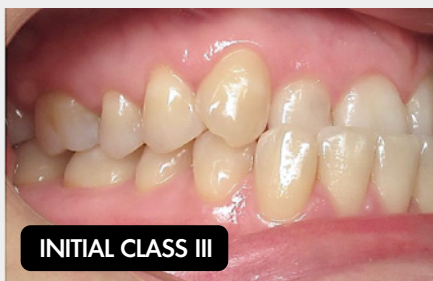ASSISTANT TIME

Doctor starts IPR with metal polishing strips

Every case is different

Sometimes we start on the initial visit...ALL PLANNED IN CLINCHECK

**CLASS III: INVISALIGN correction with IPR [in the lower arch]**



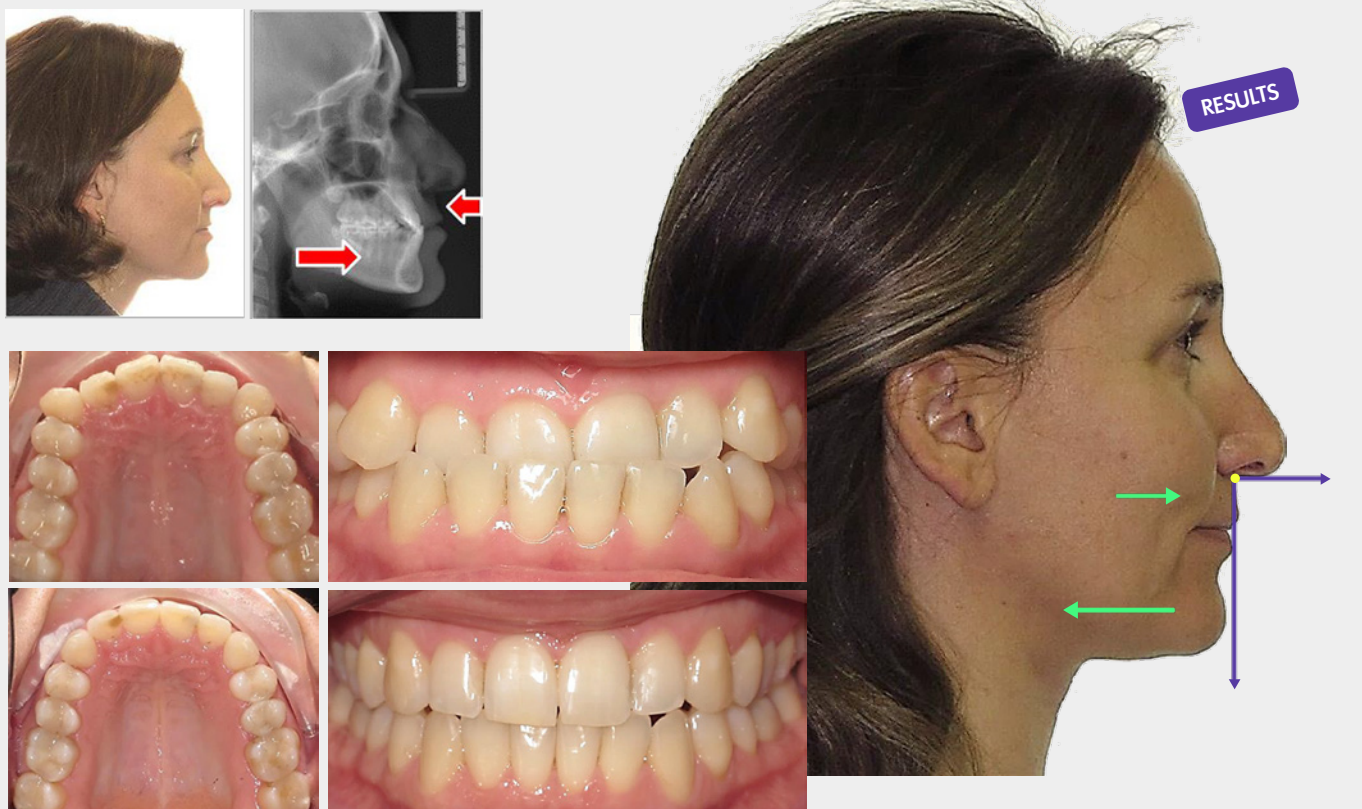
Class III with prognathic mandible, mild maxillary retrognathia, poor upper alignment, complete anterior crossbite



# Samples from previous courses

3rd COURSE Clear Removable Aligners for Total Treatment

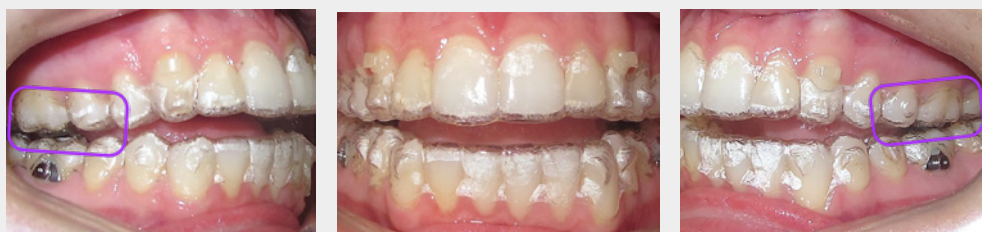## CLASS III: INVISALIGN correction with IPR [in the lower arch]



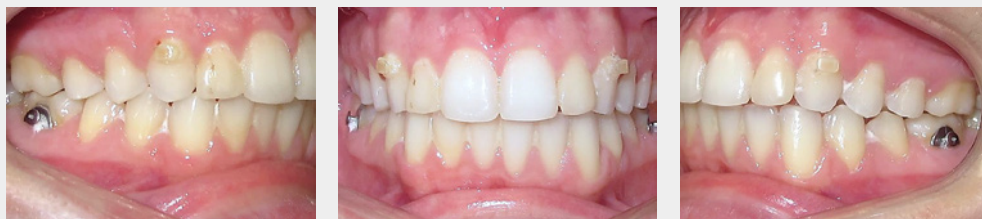Class III with prognathic mandible, mild maxillary retrognathia, poor upper alignment, complete anterior crossbite.

## OPENBITE CORRECTION: Severe with molar occlusion only

THE WOW: BITE BLOCK EFFECT



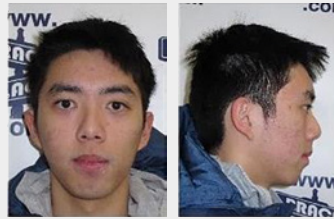

Refinement stage.....bite closure almost ideal



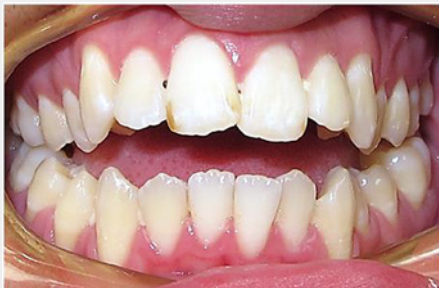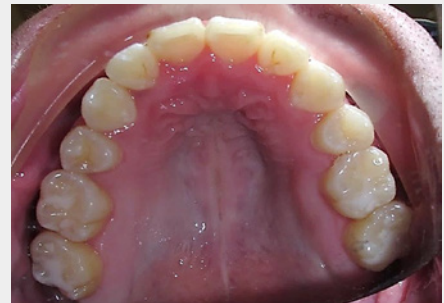# Samples from previous courses

3rd COURSE Clear Removable Aligners for Total Treatment

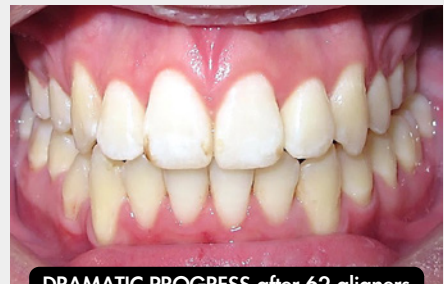## OPENBITE CORRECTION: Severe with molar occlusion only



THE SUPER-WOW...  
Space closure from extractions and retraction of upper anteriors and continued open bite closure.

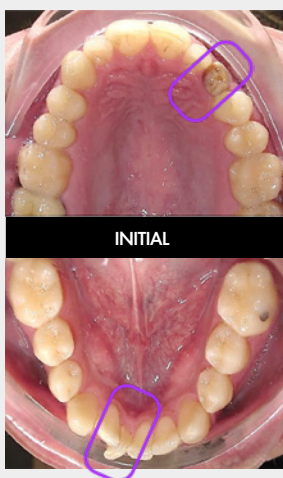


REFINEMENT

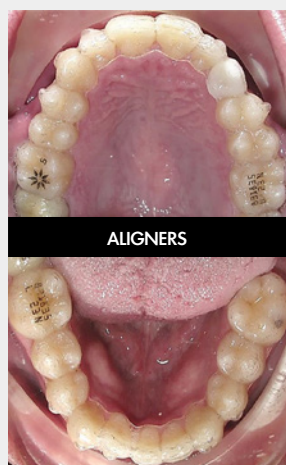

DRAMATIC PROGRESS after 62 aligners

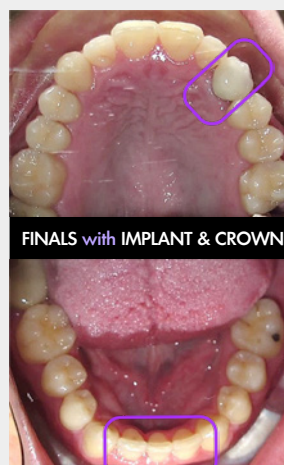## INTERDISCIPLINARY TX: Create ideal spacing for canine implant.



INITIAL



ALIGNERS



FINALS with IMPLANT & CROWN

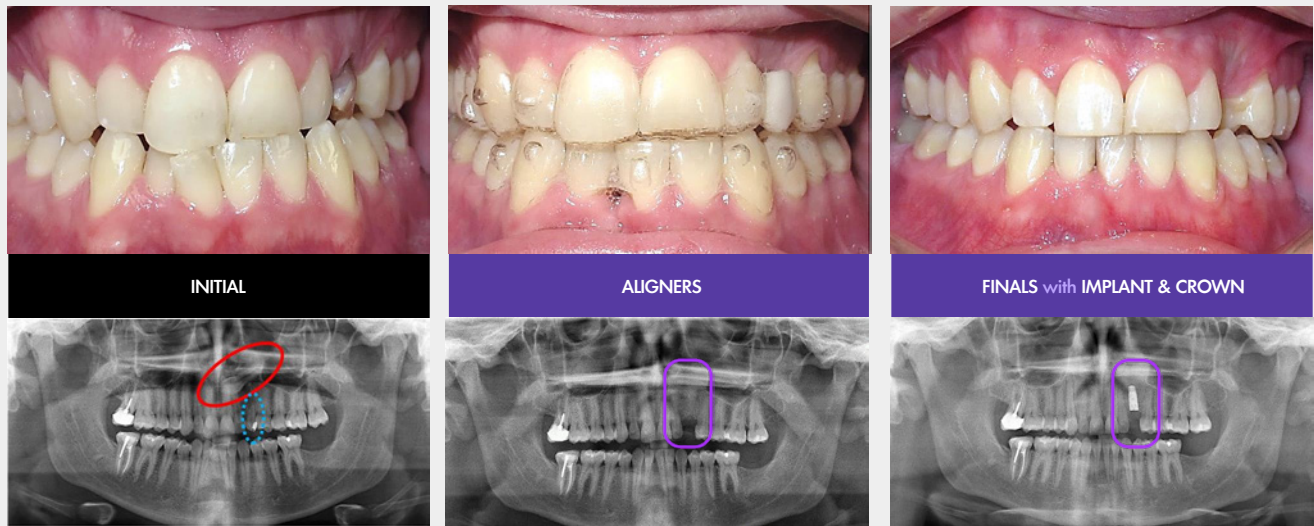
OCCLUSAL VIEWS: eliminated lower crowding, corrected Class III, provided space for ideal OB/OJ



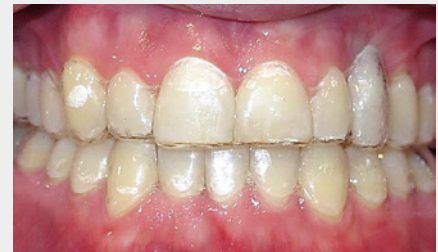# Samples from previous courses

3rd COURSE Clear Removable Aligners for Total Treatment

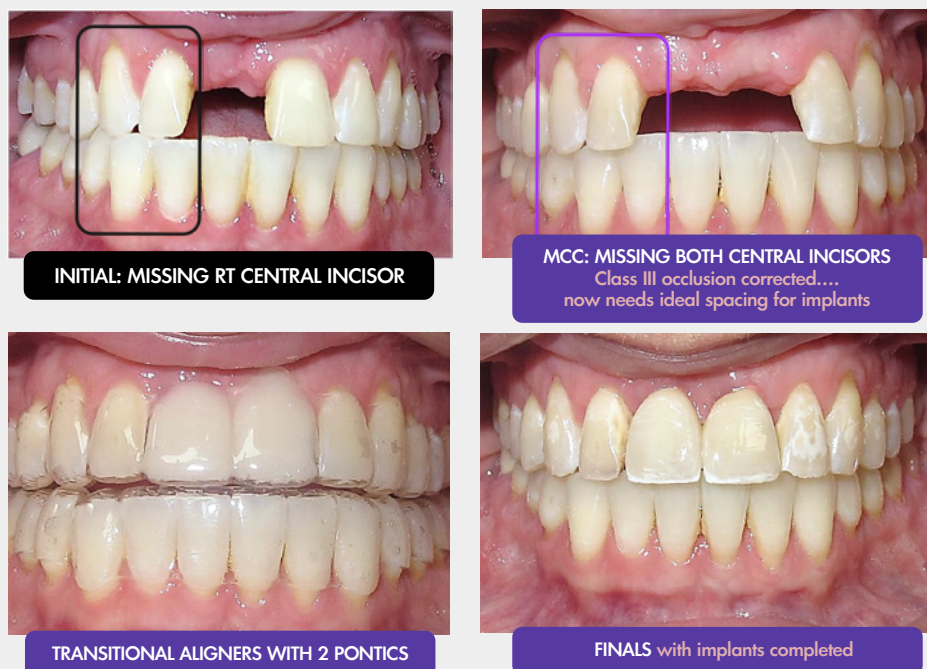## INTERDISCIPLINARY TX: create ideal spacing for canine implant



FRONTAL VIEW: eliminated lower crowding, corrected Class III, provided space for ideal OB/OJ



## MISSING UPPER RT CENTRAL INCISOR & now requires extraction of other central incisor: will require implants and transitional restorations

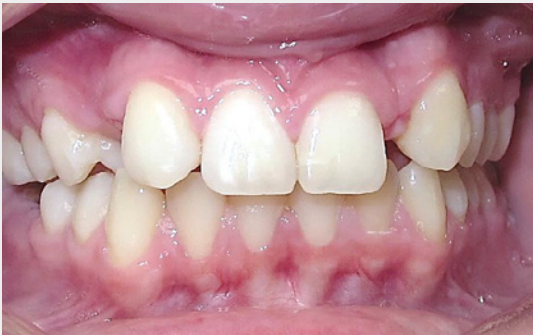

# Samples from previous courses

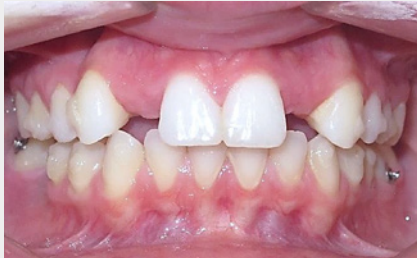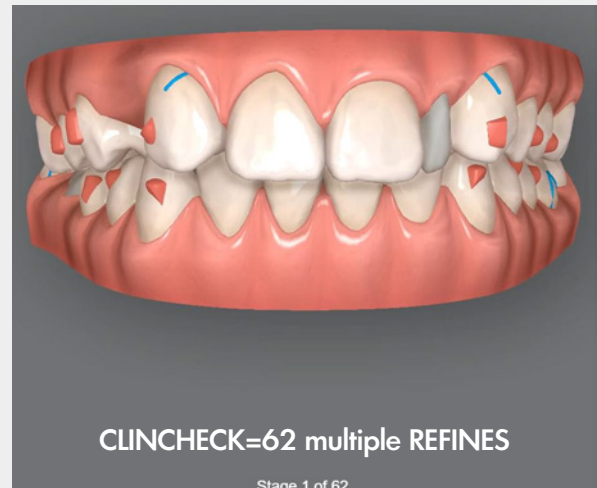3rd COURSE Clear Removable Aligners for Total Treatment

## Treatment Progress: frontal view

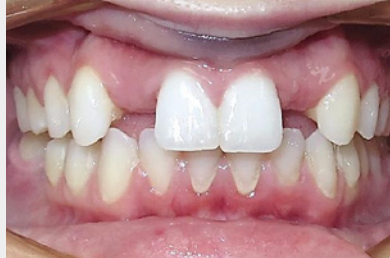Agenesis of both upper lateral incisors with considerable movement required



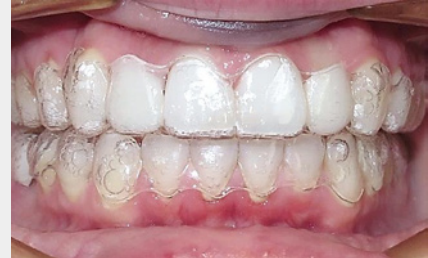INITIAL: Missing BOTH upper laterals  
In different positions



Attachments and Class II buttons



FINAL alignment



Clear retainers with pontics

## LECTURE COURSE

# New Ideas in Early Interceptive Treatment

## COURSE CONTENT

### PALATAL EXPANSION

The use of laser sintered expanders  
Elimination of separators and fitting of bands

### CLASS III

Alternatives to the Face Mask

### VERTICAL OPEN BITES

Alternatives to the "dreaded" tongue loops

### CLEAR REMOVABLE ALIGNERS

Do they have a place in early treatment

How to treat younger patients with less compliance and easier to use appliances



This is part of a larger 2-year hands-on course offered by Merimna Institute. This course focuses on patients in the mixed dentition. Ideal for Pediatric Dentists to attend

- The new and very patient friendly expander: The Laser Sintered Expanders
- Class III new approaches to eliminate Face Masks and difficult cooperation
- Early treatment of Vertical Open Bites without difficult tongue loops
- New Concepts for easier non-compliant early treatment
- Strategies for the use of clear removable aligners in the mixed dentition

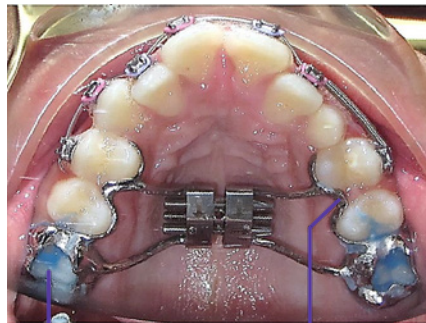
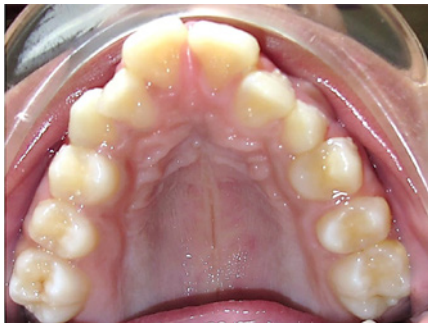

# Samples from previous courses

4th COURSE New Ideas in Early Interceptive Treatment

## WHAT IS NEW with EXPANDERS ?

### LASER SINTERED EXPANDERS IN THE DIGITAL ERA



Open occlusal surface

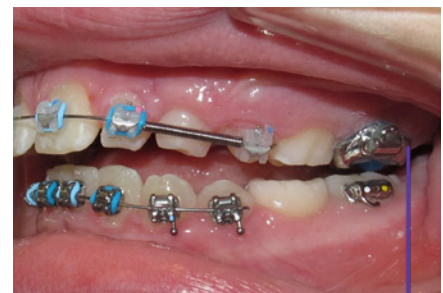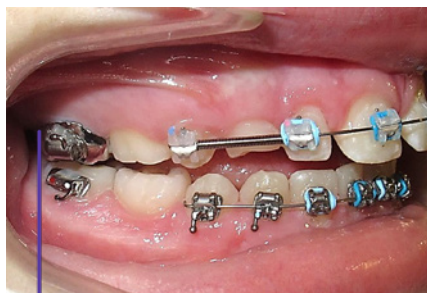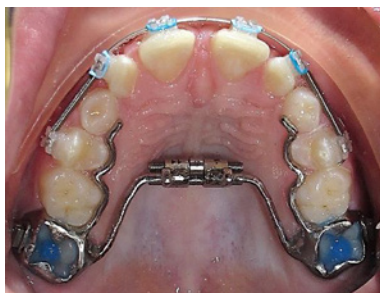Bonded on lingual surfaces of premolars occlusal surface

WITH BUCCAL TUBES  
MINI STYLE EXPANDER



WITH BUCCAL TUBES  
MINI STYLE EXPANDER

AFTER 8 MONTHS OF TREATMENT



Improved hygiene..bands do not fit subgingivally

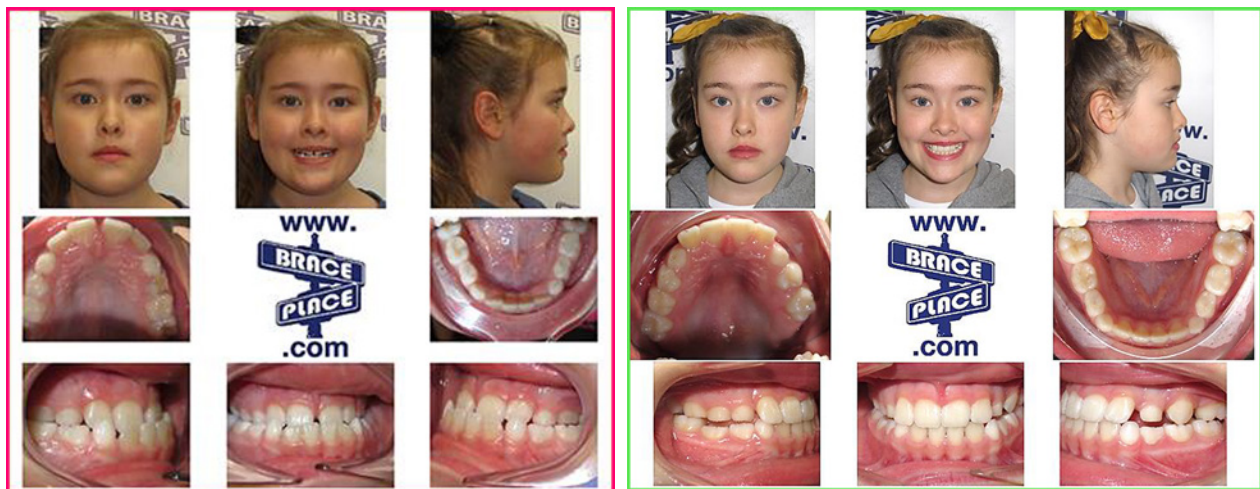

# Samples from previous courses

4th COURSE New Ideas in Early Interceptive Treatment

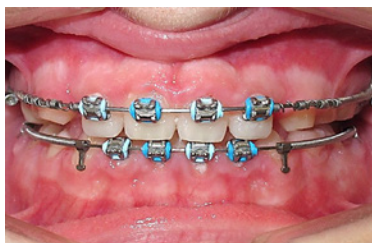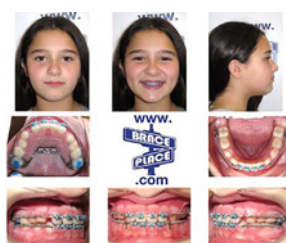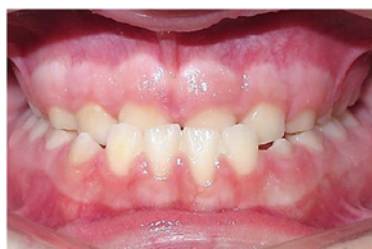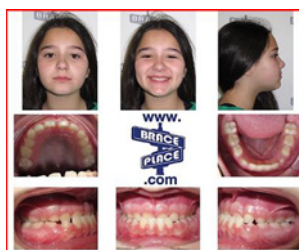## “CLASS III POTENTIAL” A Different Approach

FINALS [AGE 9.3] ...WITH 12 MONTHS ACTIVE TREATMENT



MODIFICATION... FULL ACTIVE ARCH IN UPPER

PROGRESS [AGE 11.2].....WITH 7 MONTHS ACTIVE TREATMENT



ANTERIOR CROSSBITE RESOLVED

BILATERAL POSTERIOR CROSSBITE RESOLVED

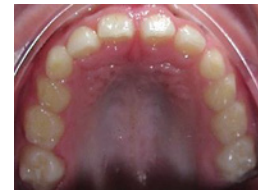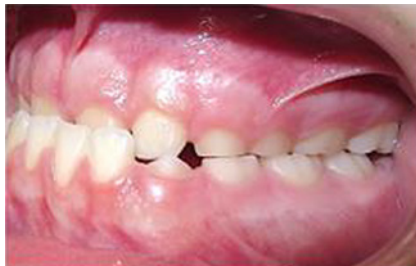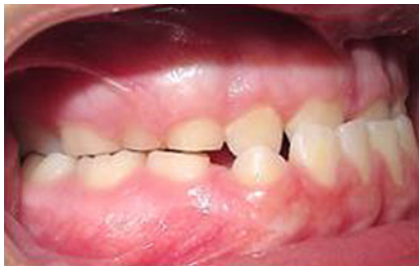CLASS III MOLARS RESOLVED

# Samples from previous courses

4th COURSE New Ideas in Early Interceptive Treatment

## "CLASS III POTENTIAL" A Different Approach

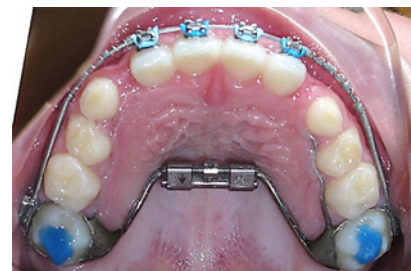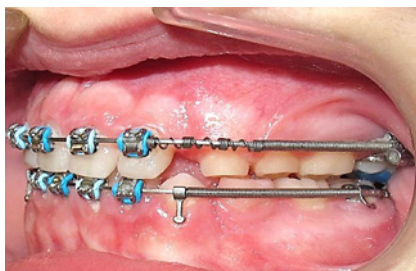
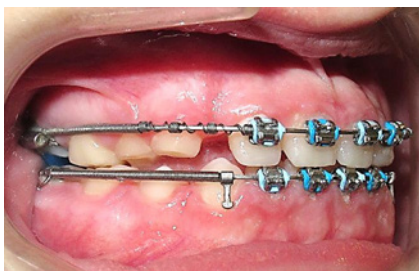
Progress [age 11.2].....with 7 months active treatment



MODIFICATION...FULL ARCH IN UPPER

BONDED U/L 2 X 4 [NOW 20 X 20 NITI ARCHES]  
FULL UPPER ARCH WITH ACTIVE/PASSIVE COIL  
PLACED TRILLIUM HOOKS IN LOWER 20 X 20 NITI ARCH  
CLASS III ELASTICS

PALATAL EXPANSION COMPLETED



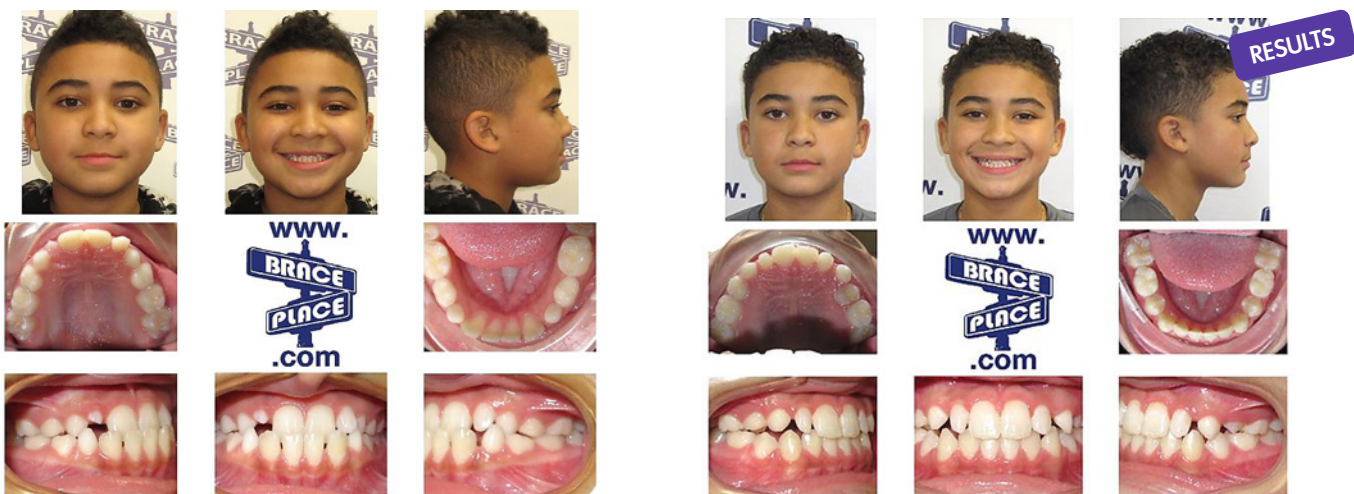SEVERE COMPLETE ANTERIOR CROSSBITE

SEVERE BILATERAL POSTERIOR CROSSBITE

Positive OB/OJ  
IDEAL CLASS I MOLARS with 7months active treatment

Maximum expansion  
Over correction with 7 months active treatment

FINALS [age 10.6].....with 18 months active treatment



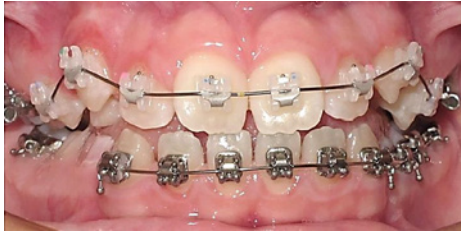
NO FACEMASK USED



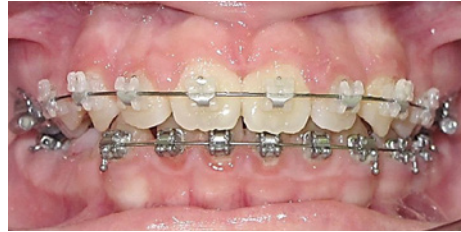# Samples from previous courses

4th COURSE New Ideas in Early Interceptive Treatment

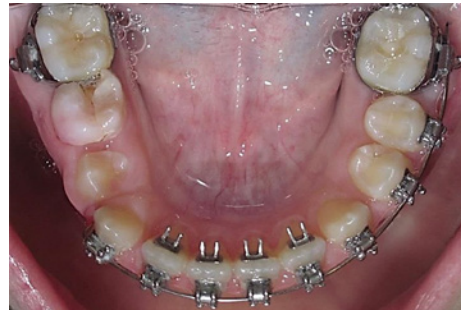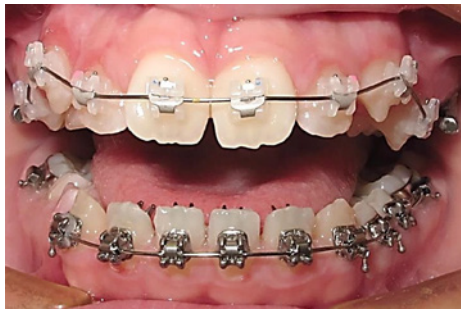## "TONGUE Tamers"



INITIAL PLACEMENT

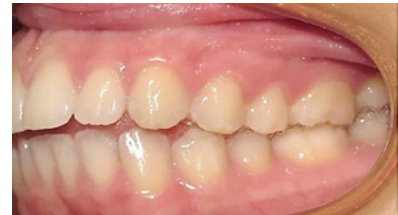
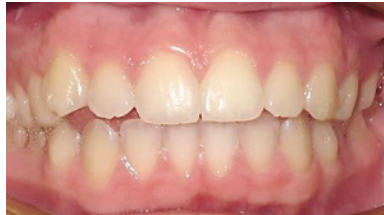
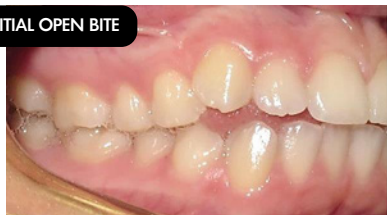EARLY PROGRESS

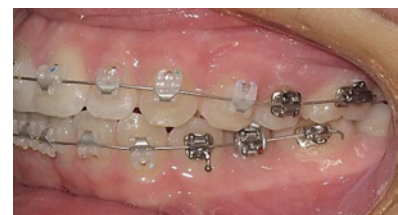
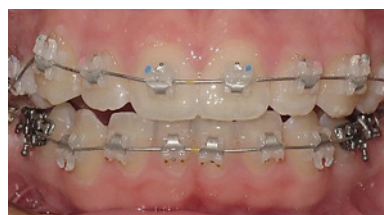
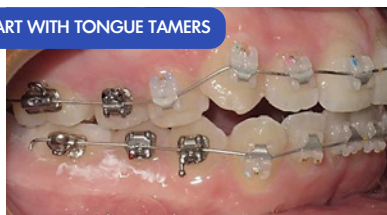Ideal tongue position  
WITH TRAINING

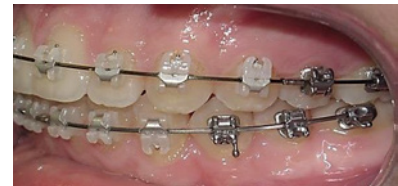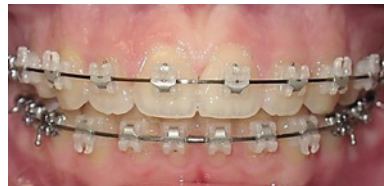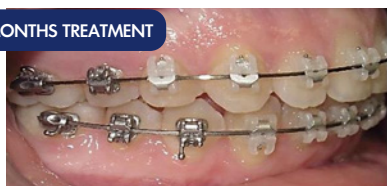INITIAL OPEN BITE



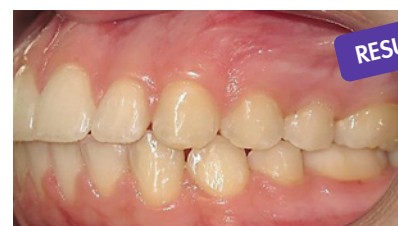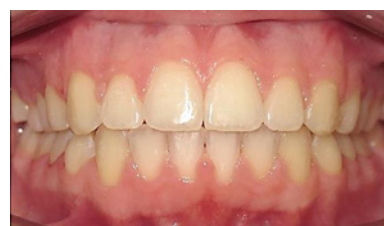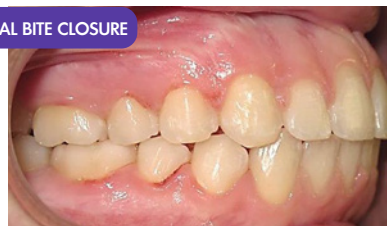START WITH TONGUE TAMERS



4 MONTHS TREATMENT



FINAL BITE CLOSURE



RESULTS

# Samples from previous courses

4th COURSE New Ideas in Early Interceptive Treatment

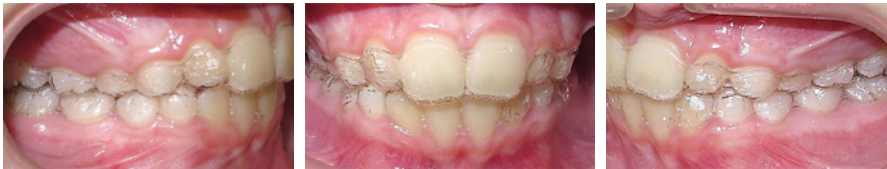## Clear Aligner Strategies

### TREATMENT in the MIXED DENTITION

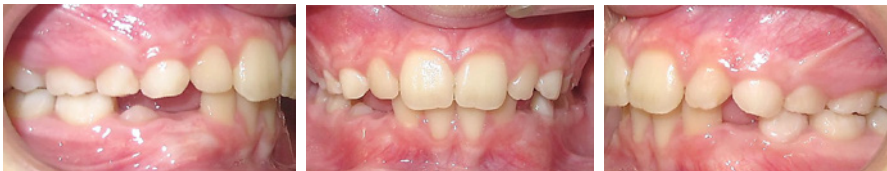CAT : Clear Aligner Treatment

#### CLEAR REMOVABLE ALIGNERS:

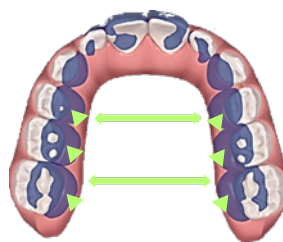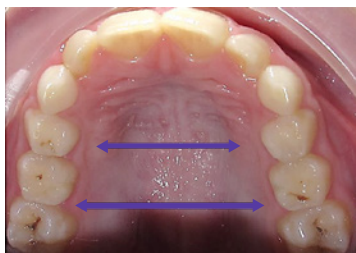
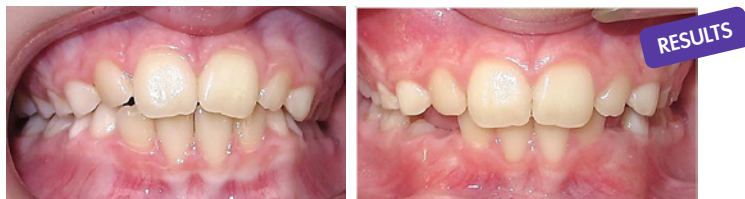"I AM 9 years old...and so mature...and I am doing television commercials"



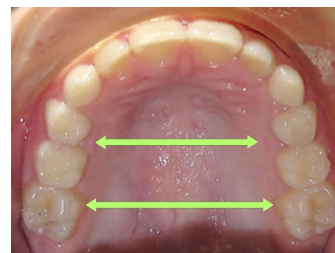
INITIAL ALIGNERS PLACED:  
Needs mild palatal expansion  
and upper anterior alignment



9 Months of aligner wear:  
ACHIEVED mild palatal expansion  
and upper anterior alignment

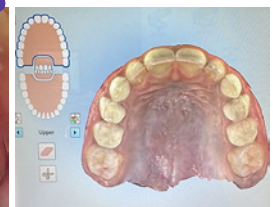
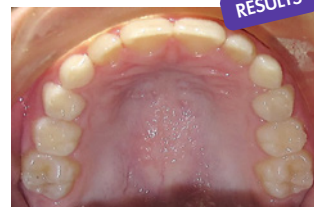
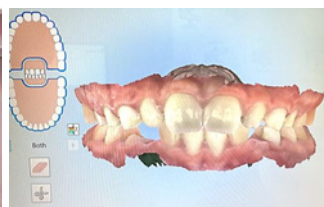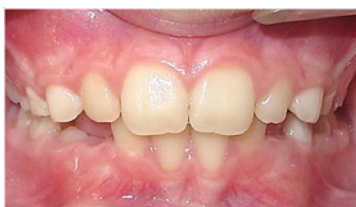Superimposition  
BLUE is pre-treatment



9 months of aligner wear:  
ACHIEVED mild palatal expansion

#### Digitally scanned for Phase I retainer





# MINOR TOOTH MOVEMENT

by DR. MARTIN B. EPSTEIN

## GENERAL INFORMATION



**Dates:** Course 1 | Friday, May 10th 2024 09:00-13:00  
Course 2 | Friday, May 10th 2024 14:00-18:00  
Course 3 | Saturday, May 11th 2024 09:00-13:00  
Course 4 | Saturday, May 11th 2024 14:00-18:00

**Course Fees:** For participation in all 4 courses 290€

**Location:** Merimna Institute  
272 A Vouliagmenis Ave.  
17343, Agios Dimitrios, Athens, Greece  
(Metro Station Agios Dimitrios)

**Language:** The official language of the Course is **English**

## REGISTRATION

**MERIMNA INSTITUTE**  
Dental Education Institution

PHONE: (+30) 210 9734000  
E-MAIL: [info@merimnaseminars.gr](mailto:info@merimnaseminars.gr)  
WEB: [www.merimnaseminars.gr](http://www.merimnaseminars.gr)

